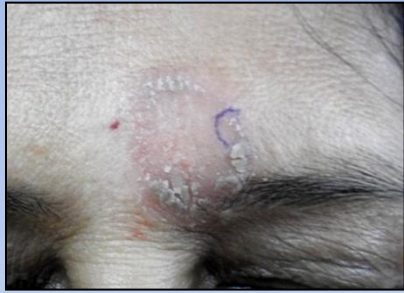

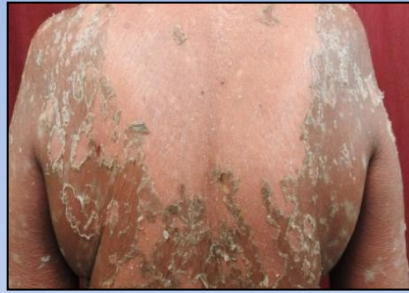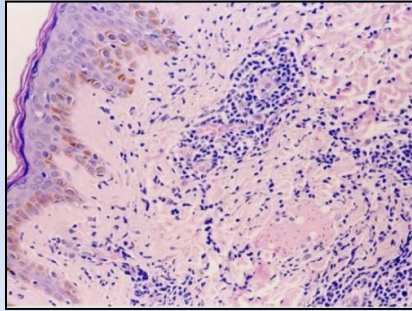
# POSTER ID:14 HISTOPATHOLOGY-A CLUE TO DIAGNOSE A GREAT IMITATOR: MYCOSES FUNGOIDES

DR. KARTAVYA BANKER 2<sup>ND</sup> YEAR RESIDENT AMCMET MEDICAL COLLEGE, AHMEDABAD

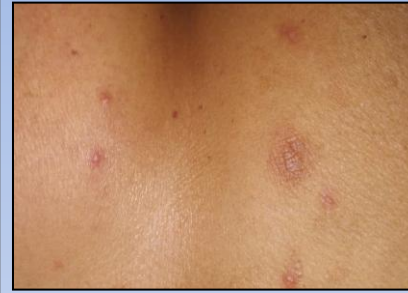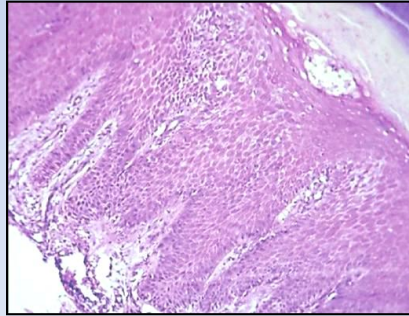
**Introduction:** Mycoses Fungoides mimics many inflammatory dermatoses clinically & histopathologically in its early stages. Here is a case of a 60 year old lady with several manifestations over a period of time with varied histological appearances. During its evolution.



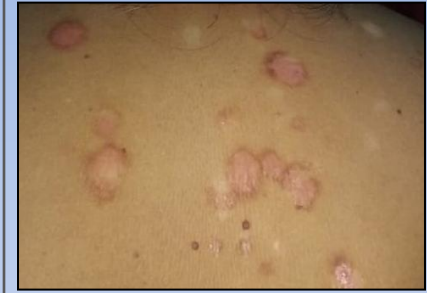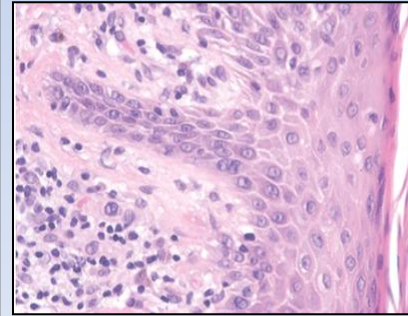
1<sup>st</sup> visit Diagnosis- ? Jessner's lymphocytic infiltrate (scaling due to treatment from outside)  
Histopath-  
Lymphocytic infiltration



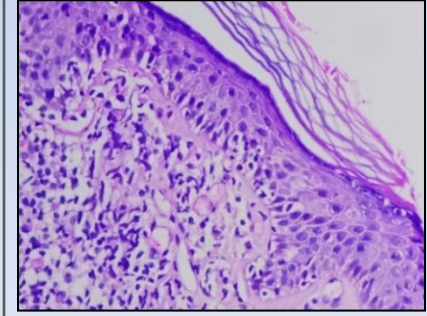
2<sup>nd</sup> visit: 2 months later  
Diagnosis- Erythroderma  
Histopath-  
Spongiotic dermatitis



3<sup>rd</sup> visit: 1 year later  
Diagnosis- ? Psoriasis ? PLC  
Histopath-  
Perivascular Dermatitis



Last visit: 2 years later  
Diagnosis- ? **MF** ? Psoriasis  
Histopath-  
Epidermotropism s/o **MF**



**Conclusion:** Diagnosing MF requires a high degree of suspicion and serial biopsies. Though most common CTCL, it is relatively rare and a good amount of clinicopathological correlation is must.